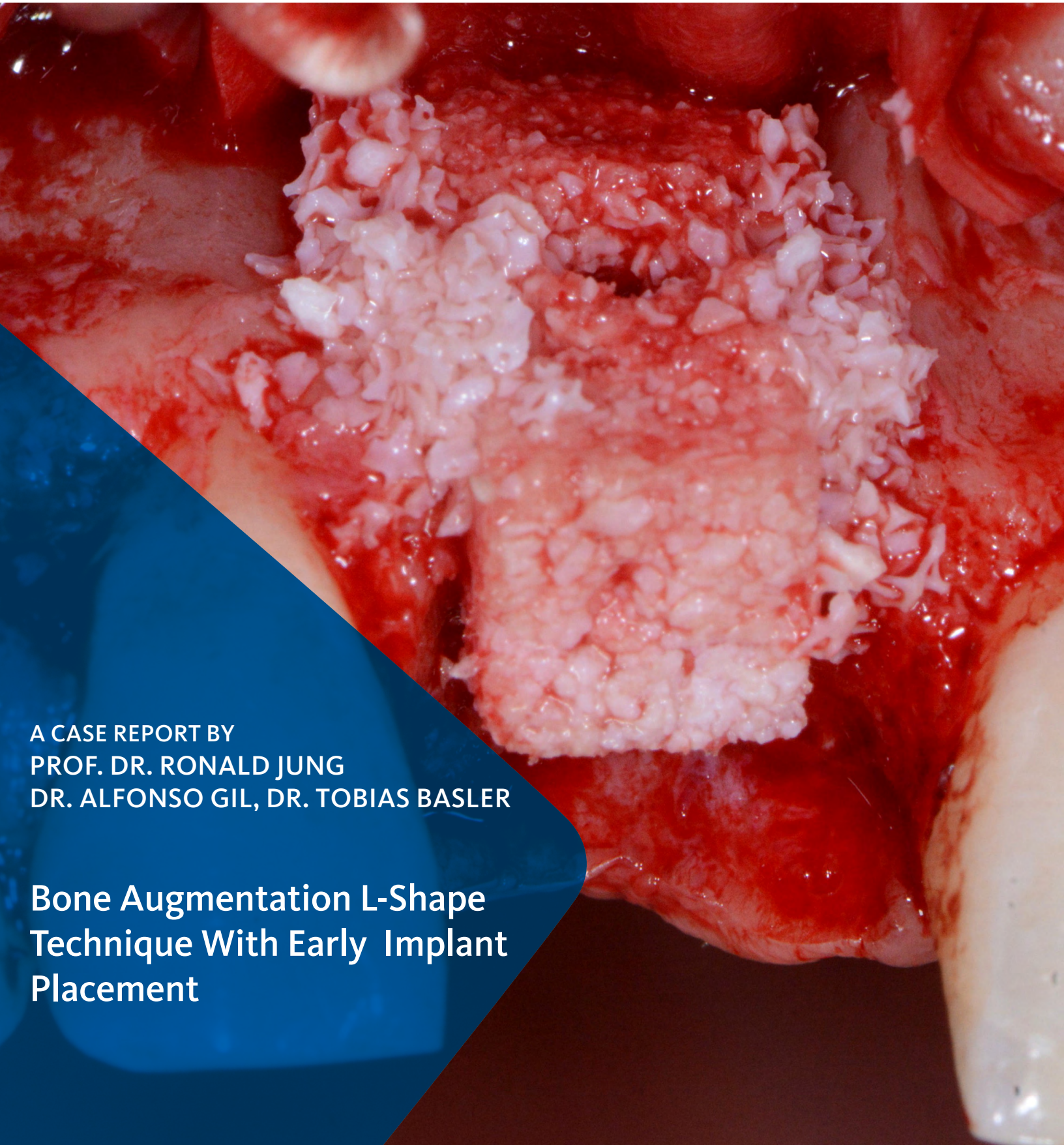
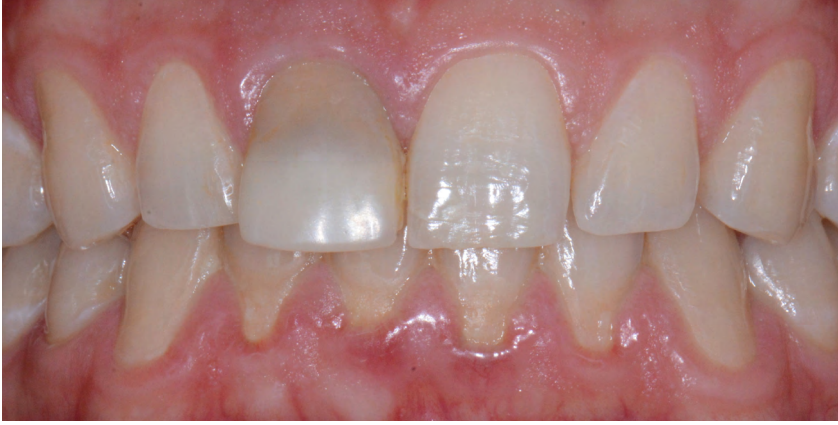


A CASE REPORT BY
PROF. DR. RONALD JUNG
DR. ALFONSO GIL, DR. TOBIAS BASLER

**Bone Augmentation L-Shape
Technique With Early Implant
Placement**



▶ The Situation

The patient presented to the clinic with a discolored tooth #8, with mobility and a history of trauma. The tooth has a horizontal fracture in the apical third of the root and has recurrent infection after the root canal treatment. The patient feels discomfort and dislikes his esthetic appearance. He would like the fractured tooth #8 removed and replaced with a fixed solution.

▶ The Risk Profile

Esthetic Risk Factors	Low Risk	Medium Risk	High Risk
Patient's health	Intact immune system	Light smoker	Impaired immune system
Patient's esthetic requirements	Low	Medium	High
Height of smile line	Low	Medium	High
Gingival biotype	Thick - "low scalloped"	Medium - "medium scalloped"	Thin - "high scalloped"
Shape of dental crowns	Rectangular		Triangular
Infection at implant sight	None	Chronic	Acute
Bone height at adjacent tooth site	≤ 5 mm from contact point	5.5 - 6.5 mm from contact point	≥ 7 mm from contact point
Restorative status of adjacent tooth	Intact		Compromised
Width of tooth gap	1 tooth (≥ 7 mm)	1 tooth (≤ 7 mm)	2 teeth or more
Soft-tissue anatomy	Intact		Compromised
Bone anatomy of the alveolar ridge	No defect	Horizontal defect	Vertical defect

Note: The fractured tooth has a periapical lesion together with a severe bone defect around the horizontal fracture.

SPECIAL INTEREST

Hard and Soft-Tissue Management

"A fractured anterior tooth needs to be replaced with an implant supported reconstruction."

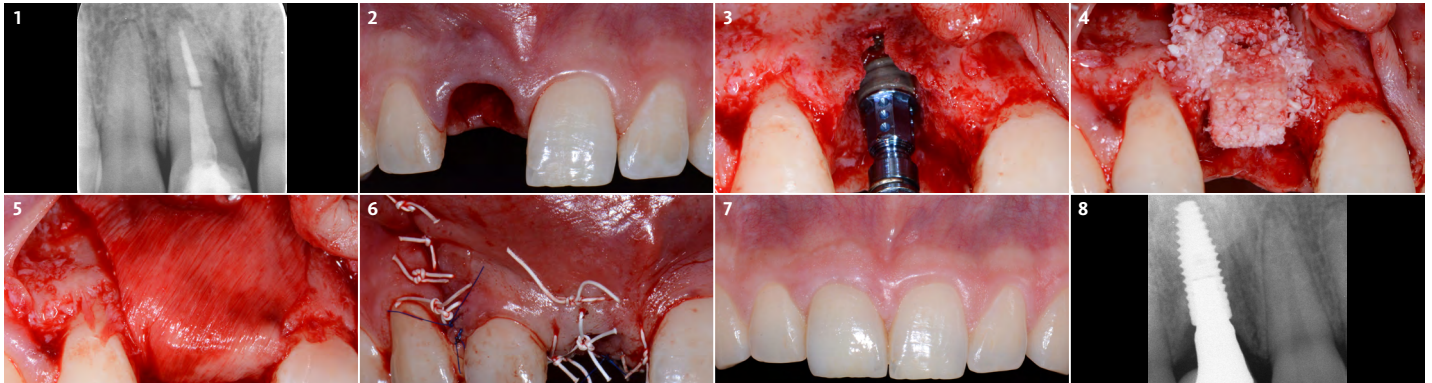
PROF.DR. RONALD JUNG • ZÜRICH, SWITZERLAND
Periodontist - Center of Dental Medicine, University of Zürich.

Prof. Dr. Jung is currently Head of the Division of Implantology, Clinic for Fixed and Removable Prosthodontics and Dental Material Science, Center of Dental Medicine at the University of Zürich. In 2006 he worked as Visiting Associate Professor at the Department of Periodontics at the University of Texas Health Science Center at San Antonio, USA (Chairman: Prof. D. Cochran). In 2008 he finalized his „Habilitation“ (venia legendi) in dental medicine and was appointed associate professor at the University of Zürich. In 2011 he received his PhD degree from the University of Amsterdam, ACTA dental school, The Netherlands. He is an accomplished and internationally renowned lecturer and researcher, best known for his work in the field of hard and soft-tissue management and his research on new technologies in implant dentistry.



▶ The Approach

To carefully extract tooth #8 and to replace it with an early stage implant placed with simultaneous guided bone regeneration through the use of Geistlich Bio-Oss Collagen® trimmed in an “L-Shape” under the protection of a Geistlich Bio-Gide®. To augment the peri-implant soft-tissue with the use of a connective tissue graft during implant healing time, increasing the overall volume of site #8. To provisionalize the implant for the development of a proper emergence profile. To deliver a definitive reconstruction which is functional and esthetic for the patient.



- 1 The tooth has had root canal treatment, has a horizontal root fracture in the apical third and exhibits with a periapical lesion.
- 2 The tooth is carefully extracted and the socket is left to heal through unassisted healing.
- 3 After 6 weeks a full thickness flap is elevated with a distal releasing vertical incision. A bone level implant is placed according to the prosthetic plan through a surgical guide. Notice the buccal dehiscence.
- 4 Geistlich Bio-Oss Collagen® is trimmed to an “L-Shape” and is placed on the buccal-occlusal side of the implant. Additional Geistlich Bio-Oss® granules are placed around the remaining gaps.
- 5 To stabilize the grafted area the bone augmentation is covered with Geistlich Bio-Gide®, which is fixated apically with two resorbable pins.
- 6 The flap is sutured with horizontal mattress and single interrupted sutures and primary closure is achieved.
- 7 The definitive layered zirconia crown was fabricated and placed. The clinical situation 5 months after implant placement, shows harmonious soft-tissue and a well integrated implant crown. The patient is satisfied with the esthetic result.
- 8 The periapical radiograph taken at the one year follow-up shows stable marginal bone levels.

4 Month Healing

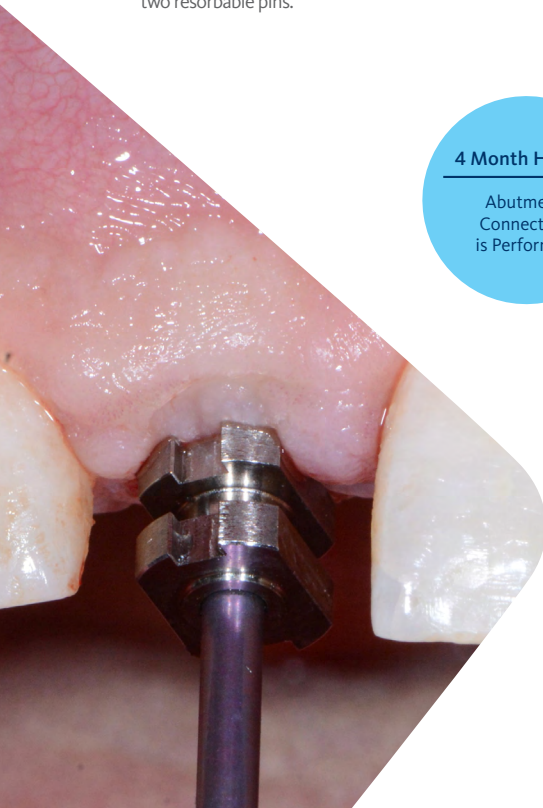
Abutment Connection is Performed

“Four months after implant placement a limited access “U”-flap was created and an implant impression was taken. The tissue was rolled to the buccal side and the abutment connection was performed.”

(See image to the left)

▶ The Outcome

The implant and its prosthetic reconstruction were successful because they provided the patient with a fixed solution with adequate function and esthetics. The implant shows stable marginal bone levels due to the proper implant placement together with the guided bone regeneration procedure. The peri-implant soft-tissue is healthy and stable with sufficient volume created by the soft-tissue augmentation. The definitive reconstruction meets the patient’s esthetic demands and is functional in occlusion.



Briefly Speaking

► Keys to Success

1. Careful tooth extraction with minimum damage to the alveolar socket walls
2. Proper implant placement, prosthetically driven, utilizing a surgical guide
3. Simultaneous guided bone regeneration with a stable bone substitute, Geistlich Bio-Oss Collagen®
4. The site is covered with a bilayered collagen membrane, Geistlich Bio-Gide® that is properly stabilized
5. Soft-tissue augmentation with the use of an autologous connective tissue graft
6. Development of an adequate emergence profile that mimics a natural tooth
7. Fabrication of a ceramic implant reconstruction that blends with the adjacent dentition and is screw-retained (when possible)

► My Biomaterials

Geistlich Bio-Gide® with its unique bilayer structure not only prevents the ingrowth of soft-tissue into the augmented site but also integrates with the surrounding soft-tissues. Bio-Oss Collagen® is comprised of the original Geistlich Bio-Oss® granules with 10% highly purified porcine collagen added for improved handling and adaptation of the material to the defect.


“Primary stability of the augmented bone volume is the clinical challenge in guided bone regeneration¹ after flap closure. In this case Geistlich Bio-Oss Collagen® has been used to augment on the buccal side of the implant.”



“By using Geistlich Bio-Oss Collagen® trimmed into an “L-Shape” covered with Geistlich Bio-Gide® a very stable horizontal and vertical bone volume around the implant is provided. This results in a stable hard and soft-tissue condition following healing. This is key for the long-term performance of an implant especially in the esthetic zone.”



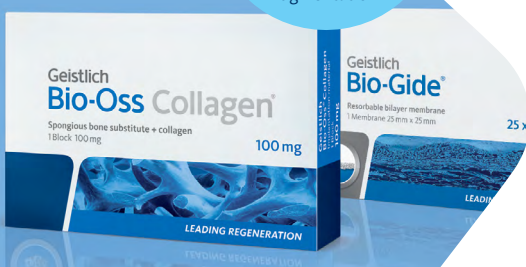Geistlich Bio-Oss Collagen® provides the versatility needed to treat a wide range of defects



Geistlich Bio-Gide® provides excellent wound stability and graft containment

Geistlich
Bio-Gide®
& Geistlich
Bio-Oss Collagen®

A winning combination
for Minor Bone
Augmentation



[Click here to view the webinar](#)

Geistlich Pharma North America, Inc.

202 Carnegie Center

Princeton, NJ 08540

Customer Care Toll-free: 855-799-5500

info@geistlich-na.com

www.geistlich-na.com

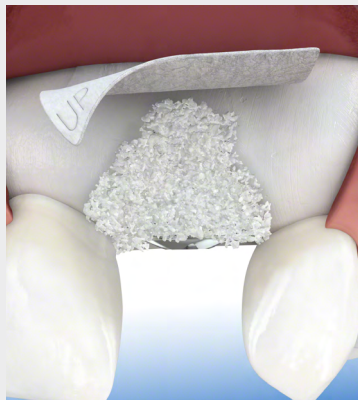ABOUT BIOBRIEF

We know that exposure to new or refined treatment approaches brings innovation to practice. Geistlich Biomaterials is pleased to introduce a periodic opportunity to get up close and personal with creative clinicians from around the world. Focused on peer-to-peer exchange, BIOBRIEF features clinically relevant cases and techniques in specific therapeutic areas – highlighted with valuable insights about materials and instrumentation, as well as KEYS TO SUCCESS.

Geistlich Biomaterials – bringing you *regeneration on time*.

▶ The Therapeutic Area

Geistlich biomaterials optimally compliments autogenous bone in Minor Bone Augmentation procedures. Due to its high resorption stability and osteoconductivity Geistlich Bio-Oss Collagen® protects human bone grafts against degradation, ensuring long-term volume preservation. When combined with Geistlich Bio-Gide® healing is undisturbed and provides significantly enhanced bone regeneration.



CAUTION: Federal law restricts these devices to sale by or on the order of a dentist or physician.

Indications:

Geistlich Bio-Oss® and Geistlich Bio-Oss Collagen® are indicated for the following uses: Augmentation or reconstructive treatment of the alveolar ridge; Filling of periodontal defects; Filling of defects after root resection, apicoectomy, and cystectomy; Filling of extraction sockets to enhance preservation of the alveolar ridge; Elevation of the maxillary sinus floor; Filling of periodontal defects in conjunction with products intended for Guided Tissue Regeneration (GTR) and Guided Bone Regeneration (GBR); and Filling of peri-implant defects in conjunction with products intended for GBR.

Warnings:

Possible complications which may occur with any surgery include swelling at the surgical site, flap sloughing, bleeding, local inflammation, bone loss, infection or pain. As Geistlich Bio-Oss Collagen® contains collagen, in very rare circumstances cases of allergic reactions may occur.

Indications:

Geistlich Bio-Gide® is indicated for the following uses: Augmentation around implants placed in immediate or delayed extraction sockets; localized ridge augmentation for later implantation; alveolar ridge reconstruction for prosthetic treatment; filling of bone defects after root resection; cystectomy and removal of retained teeth and guided bone regeneration in dehiscence defects.

Warnings:

As Geistlich Bio-Gide® is a collagen product allergic reactions may not be totally excluded. Possible complications which may occur with any surgery include swelling at the surgical site, flap sloughing, bleeding, dehiscence, hematoma, increased sensitivity and pain, bone loss, redness and local inflammation.

For more information on contraindications, precautions, and directions for use, please refer to the Geistlich Bio-Oss Collagen® and Geistlich BioGide® Instructions for Use at:

www.geistlich-na.com/ifu

REFERENCES:

1. Mir-Mari J et al. (2017). Clin Oral Implants Res. 28(6):631-639.